

# 博士学位論文

大腸鋸歯状病変に関する研究

JNET type 1 病変における Sessile serrated  
lesion の内視鏡的診断能と選択的切除の妥当性

近畿大学大学院

医学研究科医学系専攻

平田大善

# Doctoral Dissertation

A multicenter prospective validation study on selective endoscopic resection of sessile serrated lesions using magnifying colonoscopy in clinical practice







November 2022

Major in Medical Sciences  
Kindai University Graduate School of Medical Sciences

**Daizen Hirata**

## 同意書

2022年11月8日

近畿大学大学院  
医学研究科長 殿共著者 戎谷 力 共著者 岩館 峰雄 共著者 櫻田 博史 共著者 服部 三太 共著者 米田 頼晃 共著者 寺本 章彰 共著者 竹野 尊 共著者 藤田 幹丸 共著者 佐野 互 共著者 松本 次弘 

## 論文題目

A multicenter prospective validation study on selective endoscopic resection of sessile serrated lesions using magnifying colonoscopy in clinical practice

下記の博士論文提出者が、標記論文を貴学医学博士の学位論文（主論文）

として使用することに同意いたします。

また、標記論文を再び学位論文として使用しないことを誓約いたします。

## 記

1. 博士論文提出者氏名

平田 大善


2. 専攻分野 医学系

消化器病態制御学


同意書


2022年 11月 4日


近畿大学大学院  
医学研究科長 殿

共著者 村上義孝 

共著者 工藤正俊 

共著者 \_\_\_\_\_ 

共著者 \_\_\_\_\_ 

共著者 \_\_\_\_\_ 

共著者 \_\_\_\_\_ 

共著者 \_\_\_\_\_ 

共著者 \_\_\_\_\_ 

共著者 \_\_\_\_\_ 

共著者 \_\_\_\_\_ 

論文題目

A multicenter prospective validation study on selective endoscopic resection of sessile serrated lesions using magnifying colonoscopy in clinical practice

下記の博士論文提出者が、標記論文を貴学医学博士の学位論文（主論文）として使用することに同意いたします。

また、標記論文を再び学位論文として使用しないことを誓約いたします。

記

1. 博士論文提出者氏名

平田 大善

2. 専攻分野 医学系

消化器病態制御学

## ***Research Article***

# ***A multicenter prospective validation study on selective endoscopic resection of sessile serrated lesions using magnifying colonoscopy in clinical practice***

Daizen Hirata <sup>a,b</sup>, Hiroshi Kashida <sup>b</sup>, Tsuguhiro Matsumoto <sup>c,d</sup>, Chikara Ebisutani <sup>e,f</sup>, Akira Teramoto <sup>a,g</sup>, Mineo Iwatate <sup>a</sup>, Santa Hattori <sup>a</sup>, Mikio Fujita <sup>a</sup>, Wataru Sano <sup>a</sup>, Yoriaki Komeda <sup>b</sup>, Yasushi Sano <sup>a,h</sup>, Yoshitaka Murakami <sup>i</sup>, Masatoshi Kudo <sup>b</sup>

<sup>a</sup> Gastrointestinal Center and Institute of Minimally-Invasive Endoscopic Care (iMEC), Sano Hospital, Kobe, Hyogo, Japan

<sup>b</sup> Department of Gastroenterology and Hepatology, Kindai University, Osakasayama, Osaka, Japan

<sup>c</sup> Department of Gastroenterology, Akashi City Hospital, Akashi, Hyogo, Japan

<sup>d</sup> Department of Gastroenterology, Nakayama clinic, Akashi, Hyogo, Japan

<sup>e</sup> Department of Gastroenterology, Hyogo Prefectural Kakogawa Medical Center, Kakogawa, Hyogo, Japan

<sup>f</sup> Hiyodori Clinic, Kobe, Hyogo, Japan

<sup>g</sup> Third Department of Internal Medicine, Toyama University Hospital, Toyama, Toyama, Japan

<sup>h</sup> Kansai Medical University, Hirakata, Osaka, Japan

<sup>i</sup> Department of Medical Statistics, Toho University, Ota, Tokyo, Japan

Running Title: Selective endoscopic resection of SSL

Corresponding Author:

Daizen Hirata

Gastrointestinal Center and Institute of Minimally-Invasive Endoscopic Care (iMEC)

Sano Hospital

2-5-1 Shimizugaoka, Tarumi-ku

Kobe, Hyogo 655-0031, Japan

Tel: 81-(78)-785-1000

E-mail: daizenhirata@gmail.com

Number of Tables: 6

Number of Figures: 2

Word count: 3797 words

Keywords: sessile serrated lesions, differential diagnosis, selective endoscopic resection, multicenter prospective study

Publishment:

S. Karger AG | Medical and Scientific Publishers | Allschwilerstrasse 10 | 4009 Basel |  
Switzerland

t + 41 61 306 11 11 | f + 41 61 306 12 34 | [www.karger.com](http://www.karger.com)

Digestion

A multicenter prospective validation study on selective endoscopic resection of sessile serrated lesions using magnifying colonoscopy in clinical practice

Hirata et al. DOI: 10.1159/000527978

The Version of Record of this article is available at  
<http://www.karger.com/?doi=10.1159/000527978>.

## **Abstract**

**Introduction:** Sessile serrated lesions (SSLs) have malignant potential for colorectal cancer in the serrated pathway. Selective endoscopic resection of SSLs would reduce medical costs and procedure-related accidents, but the accurate endoscopic differentiation of SSLs from hyperplastic polyps (HPs) is challenging. To explore the differential diagnostic performance of magnifying colonoscopy in distinguishing SSLs from HPs, we conducted a multicenter prospective validation study in clinical practice.

**Methods:** Considering the rarity of diminutive SSLs, all lesions  $\geq 6$  mm that were detected during colonoscopy and diagnosed as type 1 based on the Japan narrow-band imaging expert team (JNET) classification were included in this study. Twenty expert endoscopists were asked to differentiate between SSLs and HPs with high or low confidence level after conventional and magnifying NBI observation. To examine the validity of selective endoscopic resection of SSLs using magnifying colonoscopy in clinical practice, we calculated the sensitivity of endoscopic diagnosis of SSLs with histopathological findings as comparable reference.

**Results:** A total of 217 JNET type 1 lesions from 162 patients were analyzed, and 114 lesions were diagnosed with high confidence. The sensitivity of magnifying colonoscopy in detecting SSLs was 79.8% (95% confidence interval (CI): 74.7–84.4%) overall, and 82.4% (95% CI: 76.1–87.7%) in the high-confidence group. These results showed that the sensitivity of this study was not high enough, even limited in the high-confidence group.

**Conclusions:** Accurate differential diagnosis of SSLs and HPs using magnifying colonoscopy was challenging even for experts. JNET type 1 lesions  $\geq 6$  mm are recommended to be resected because selective endoscopic resection has a disadvantage of leaving approximately 20% of SSLs on site.

## **Introduction**

Colorectal cancer (CRC) is the third most common cancer worldwide [1], and adenomas were long thought to be the only precursor lesion for CRC development. However, colorectal serrated lesions have emerged as another key pathway contributing to CRC development, and it is now believed that a significant portion of sporadic CRC arises from serrated precursor lesions [2, 3]. In colorectal serrated lesions, traditional serrated adenomas, sessile serrated lesions (SSLs), and sessile serrated lesions with dysplasia (SSLDs) are considered to be precursors to CRC.

Although no clear endoscopic diagnostic criteria exist for SSLs, the European Society of Gastrointestinal Endoscopy recommends in their guidelines that all polyps should be resected except for diminutive ( $\leq 5$  mm) rectal and rectosigmoid polyps that are predicted to be hyperplastic with high confidence [4]. On the other hand, if SSLs could be discriminated from hyperplastic polyps (HPs) and selectively resected, it would reduce medical costs, procedure-related accidents, and the burden on patients and endoscopists. We have revealed that the percentage of SSLs in serrated lesions increases with size and that the percentage of SSLDs in SSLs also increases with the size, and all SSLDs were 6 mm or larger [5, 6]. Although several studies on the clinical and endoscopic characteristics of SSLs have been reported [7-22], they were mostly designed as either single-center retrospective or prospective studies using still images. No multicenter prospective study has been performed to determine whether endoscopists can accurately differentiate between SSLs and HPs in clinical practice.

The Japan narrow-band imaging (NBI) expert team (JNET) classification, the latest magnifying NBI classification, has high diagnostic performance in differentiating neoplasm from non-neoplasm and in predicting the distance of cancer invasion [23-25]. Thus, it has been widely used for endoscopic diagnosis of colorectal lesions. Of note, JNET type 1 lesions include both SSLs and HPs, and it is still unclear whether SSLs and HPs can be distinguished. In recent years, there have been discussions that assume that SSLs can be differentiated from HPs and selectively resected. We recognize the weaknesses and limitations of endoscopic diagnosis and anticipate that accurate differential diagnosis of SSLs in JNET type 1 lesions may be challenging in clinical practice. To explore the differential diagnostic performance of magnifying colonoscopy in distinguishing SSLs from HPs, we conducted a multicenter prospective study of the differential diagnosis of SSLs in JNET type 1 lesions in clinical practice.

## **Materials and Methods**



This prospective study was performed at four endoscopy centers (one university hospital, two regional core hospitals, and one high-volume endoscopy center) and conducted in accordance with the Declaration of Helsinki and the Clinical Research Act. This study protocol was reviewed and approved by the Research Ethics Review Committee on December 5th, 2019 (case number: 201912-02); it was also pre-registered in UMIN-CTR (University Hospital Medical Information Network Clinical Research Registration System) as UMIN 000037543.

### **Patients**

All patients aged 20 years or older with at least one JNET type 1 lesion  $\geq 6$  mm who underwent colonoscopy at one of the four endoscopy centers were included. Written informed consent was obtained from all participants. Pregnant or lactating patients, patients with a history of colectomy (excluding appendicectomy), taking antiplatelet or anticoagulant medication, with inflammatory bowel disease, polyposis coli, or colorectal cancer, and other concomitant severe diseases were excluded.

### **Endoscopists and quality control**

Twenty expert endoscopists were involved in this study and were defined as fellows qualified by the Japan Gastroenterological Endoscopy Society, including three founding members of the JNET classification. These 20 expert endoscopists were authorized after receiving a two-hour lecture on recent reports and reviews on the endoscopic features of SSLs. No further quality control was performed because it would have taken away from the current state of actual clinical practice.

### **Endoscopic and histopathological diagnosis of SSL**

Whenever the endoscopist detected a lesion  $\geq 6$  mm during colonoscopy, he or she first performed magnifying NBI and made a diagnosis according to the JNET classification. If the lesion was suspected to be JNET type 1, detailed re-evaluation with white light imaging (MLI) and NBI were consecutively performed. Based on these observations, a diagnosis of SSL or HP was made and recorded.

Additionally, the confidence level of the endoscopic diagnosis and the presence or absence of the findings of each of the eight candidates were recorded. The diameter and location of each lesion were also registered. Regarding the location, the right colon was defined to be proximal to the splenic flexure.

The diagnostic criteria for SSL in this study were not strictly defined. Each endoscopist diagnosed SSL or HP by considering comprehensive findings obtained through endoscopic observations because there is no consensus regarding the diagnostic criteria for SSL and because diagnosis is made based on the comprehensive judgment of each endoscopist in clinical practice.

The following eight terminologies were enrolled to describe the endoscopic features suggestive of SSLs: irregular shape, indistinctive border, cloud-like surface, mucus cap, rim of debris, dilated vessels, dilated crypts, and inverted growth pattern. These eight features were the characteristic findings of sessile serrated adenoma/polyps (SSAPs) [26]. There was still no consensus regarding endoscopic findings of SSLs; the diagnosis of SSL was made based on the findings of SSAPs in clinical practice. Therefore, these eight features of SSAPs were adopted by the candidates as their characteristic findings of SSLs. These eight candidate findings of SSLs are shown in Figure 1. For each JNET type 1 lesion  $\geq 6$  mm, all eight findings had to be marked as either present or absent simultaneously. Subsequently, the endoscopic treatment was performed for all JNET type 1 lesions  $\geq 6$  mm and the resected specimen was submitted for histopathological examination. The pathological diagnosis was made in each institution and all pathologists were blinded to the study. These endoscopic and histopathological diagnoses were collected independently and registered in a database. Lesions for which histopathological tissue could not be retrieved and lesions with a histopathological diagnosis other than SSL or HP were excluded from the analysis.

Histopathological diagnosis was based on the 5th edition of the World Health Organization (WHO) Classification of Tumors of the Digestive System, published in 2019 [27]. Histological criteria for sessile lesions and polyps: A single unequivocal distorted crypt was the only requirement for the diagnosis of a SSL. The distortion of crypt architecture can include horizontal growth along the muscularis mucosae, dilatation of the crypt base, serrations extending into the crypt base, and asymmetrical proliferation. Flat serrated lesions/polyps with no typical SSL-type crypts are diagnosed as HPs by exclusion. Mild symmetrical crypt dilatation, occasional branching, and goblet cells at the base of crypts are insufficient for the diagnosis of SSL.

### **Study outcomes**

For examining the validity of selective endoscopic resection of SSLs using magnifying colonoscopy in clinical practice, we used the sensitivity of endoscopic diagnosis of SSLs in JNET type 1 lesion  $\geq 6$  mm in the analysis. Since it is clinically important to prevent leaving SSLs on site, the sensitivity of endoscopic diagnosis was at most suitable measure for the description. The diagnostic performance, such as specificity, positive predictive value, and negative predictive value of SSLs in JNET type 1 lesions  $\geq 6$  mm was also calculated by comparing the endoscopic diagnosis with the histopathological diagnosis as the gold standard. The usefulness of the differential diagnosis was statistically analyzed and judged by whether the upper limit of the 95% confidence interval (CI) for sensitivity reached 90%. If the upper limit of the 95% CI for sensitivity did not reach 90%, the differential diagnosis is not

sensitive enough, and selective endoscopic resection is not recommended due to the risk of leaving more than 10% SSLs on site.

We also analyzed to what extent the combined use of confidence levels contributed to improving the diagnostic performance. The diagnostic performance in the high confidence (HC) group, low confidence (LC) group, and overall were compared. In addition, the appearance ratio of the eight characteristic findings in the SSL and HP groups was calculated. Furthermore, multivariate logistic regression analysis was performed to determine the usefulness of the eight characteristic findings in the differential diagnosis of SSL.

### **Sample size calculation**

We tried to set a sample size to get a reasonable width of confidence interval of sensitivity. This calculation was based on earlier studies [7-22, 26]. The earlier study of Yamashina et al. reported the diagnostic performance: sensitivity of 0.84 (0.71–0.93) for SSL diagnosis based on dilated crypts [20]. Based on this report, we calculated the sample size that the sensitivity was 0.84 and their upper 95% confidence limit was 90% (n=144). In this calculation, no multiple lesions in the same cases were admitted. Considering the potential case of multiple lesions in one case, we finally set 180 lesions for the required numbers for enrollment in this study.

### **Statistical analyses**

For the sensitivity, the Fisher's exact test for binary data and the Mann–Whitney U test for countable data were used. For exploring the usefulness of the eight characteristic findings, a multivariate logistic regression model was used to estimate odds ratios (ORs) and 95% CIs. This model included the following eight variables: irregular shape, indistinct border, cloud-like surface, mucus cap, rim of debris, dilated vessels, dilated crypts, and inverted growth pattern. R Version 4.0.0 (R Core Team 2020, Vienna, Austria) was used for the statistical analysis in this study.  $P < 0.05$  was considered statistically significant.

## **Results**

### **Study population**

In four institutions, 4,397 and 4,336 patients were recruited and admitted, respectively, between December 2019 and October 2020. Among them, 241 lesions from 185 cases were enrolled and no cases were denied enrollment. One lesion was excluded due to ineligibility, and 23 lesions were excluded due to non-serrated histology, eventually including 217 JNET type 1 lesions from 162 cases in the final analysis. The study flowchart is shown in Figure 2.

As shown in Table 1, the patients' mean age was  $65.7 \pm 10.3$  years, and the male/female ratio was 89/73. A total of 146 lesions (67.3%) were in the right colon. The mean diameter of JNET type 1 lesions was  $9.5 \pm 5.0$  mm, and 148 lesions (68.2%) were between 6–9 mm. Pathologically, 129 lesions were diagnosed as SSLs and 88 lesions as HPs. The percentage of pathological SSLs was 49.3% in 6–9 mm JNET type 1 lesions and 81.1% in >10 mm JNET type 1 lesions. Between SSLs and HPs, there were no significant differences in age; however, there were significant differences in sex ratio, location, and size.

## **Study outcomes**

### *Diagnostic performance in discriminating SSLs from HPs*

Endoscopically, 139 lesions were diagnosed as SSLs and 78 lesions as HPs, and histopathologically, 129 lesions were diagnosed as SSLs and 88 lesions as HPs, as shown in Table 2. Table 3 shows that the diagnostic performance for SSLs in JNET type 1 lesions  $\geq 6$  mm was as follows: sensitivity 79.8% (95% CI 74.7–84.4), specificity 59.1% (49.8–62.4), accuracy 71.4% (65.3–76.9), positive predictive value 74.1% (69.3–78.4), and negative predictive value 66.7% (58.1–74.3). The sensitivity of each institution was 75.0%, 79.2%, 80.0%, and 80.4%, respectively, with no significant variations among the institutions.

### *Diagnostic performance and confidence levels*

A total of 114 lesions (52.5%) were endoscopically diagnosed with high confidence and 103 lesions (47.5%) were diagnosed with low confidence. In the high confidence group, 75 lesions were diagnosed as SSLs and 39 as HPs endoscopically, whereas 74 lesions were diagnosed as SSLs and 40 lesions as HPs histopathologically. The diagnostic performance of the high confidence group was 82.4% (76.1–87.7) for sensitivity, 65.0% (53.3–74.7) for specificity, and 76.3% (68.1–83.1) for accuracy. The upper limit of the 95% CI for sensitivity was 87.7%.

### *Appearance ratio of the eight endoscopic findings*

As shown in Table 4, the mean number of the eight endoscopic findings recognized in the SSL and HP groups was 2.76 and 1.52, respectively. The appearance rates of the eight findings in the SSL vs. HP groups were: irregular shape 41.9% vs. 23.9%, indistinct border 38.0% vs. 20.5%, cloud-like surface 20.9% vs. 8.0%, mucus cap 62.0% vs. 33.0%, rim of debris 16.3% vs. 9.1%, dilated vessels 51.9% vs. 34.1%, dilated crypts 44.2% vs. 20.5%, and inverted growth pattern 0.78% vs. 3.4%. Table 5 shows the appearance ratio of the eight findings in SSLs and HPs and the P-value between them. Except for inverted growth, seven of the eight endoscopic findings were more frequently observed in SSLs, and

the appearance rates of six findings (irregular shape, indistinct border, cloud-like surface, mucus cap, dilated vessels, and dilated crypts) were significantly higher in SSLs.

#### *Multivariate logistic regression analysis of the eight endoscopic findings for SSLs*

Multivariate logistic regression analysis was used to evaluate how useful each of the eight endoscopic findings (irregular shape, indistinct border, cloud-like surface, mucus cap, rim of debris, dilated vessels, dilated crypts, inverted growth pattern) were in the differential diagnosis, with each finding as an independent factor. As shown in Table 6, the odds ratios for the eight endoscopic findings were 1.884, 1.811, 2.543, 2.262, 1.760, 1.997, 1.819, and 0.085, respectively. Only two findings, mucus cap and dilated vessel, were statistically significant. The area under the receiver operating characteristic curve using the eight findings was 0.727, and that of only the mucus cap and dilated vessel was 0.664.

### **Discussion/Conclusion**

This is the first multicenter prospective study to clarify the differential diagnostic performance of magnifying colonoscopy in distinguishing SSLs from HPs in clinical practice. In the present study, the sensitivity of the endoscopic diagnosis of SSLs in JNET type 1 lesions  $\geq 6$  mm was 79.8% (95% CI, 74.7–84.4). The upper limit of the 95% CI for sensitivity was less than 90%. This result statistically showed that the probability of sensitivity exceeding 90% is less than 2.5%. The differential diagnosis of SSLs in JNET type 1 lesions  $\geq 6$  mm was suggested to be challenging even by expert endoscopists. If selective endoscopic resection is performed based on endoscopic diagnosis, 20.2% of SSLs are potentially misdiagnosed as HPs and left on site. The diagnostic performance using magnifying colonoscopy is considered inadequate for selective endoscopic resection of SSLs.

There are two hypotheses as to why the SSL differentiation was not sufficiently sensitive. First, histopathological features of SSLs are difficult to observe endoscopically. Unlike adenomatous lesions, the histopathological feature of SSLs is “distorted crypt” that refers to horizontal growth along the muscularis mucosae, dilatation of the crypt base, serrations extending into the crypt base, and asymmetrical proliferation [27]. Since all these histopathological features are expressed in the crypt base, distorted crypts are difficult to detect by colonoscopy, which primarily observes surface structures. This hypothesis is supported by Table 4 showing that 48.8% of the SSLs had only two or fewer findings and six SSLs had no findings. Furthermore, the 5th edition of the WHO Classification of Tumors of the Digestive System allows for the diagnosis of SSL even if there is one obvious distorted crypt. In practice, it would be challenging to confirm by colonoscopy that there is not a single distorted crypt within the lesion. Close examination of the pathology specimens in this study

revealed 11 lesions (8.5%) with only a small number of distorted crypts. Of these 11 lesions, only six could be diagnosed as SSL even by magnifying colonoscopy.

The eight characteristic endoscopic findings of SSAPs were not specific to SSLs and they were often observed in SSLs and HPs. Table 4 shows that while an average of 2.76 endoscopic findings were noted in SSLs, an average of 1.52 findings were also recognized in HPs, and 79.5% of HPs showed at least one of the eight findings. Although six of the eight findings were statistically more frequent in SSLs, these results only showed the difference in frequency and did not indicate that a differential diagnosis was possible.

Secondly, the study was conducted as a prospective study in clinical practice. Unlike studies using static images, the endoscopist must manage the patient, operate the colonoscope, observe the lesion in detail, and make a diagnosis and treatment plan in a short period of time. Inadequate bowel preparation or excessive intestinal peristalsis makes detailed observation difficult. Therefore, the accuracy of the differential diagnosis in actual clinical practice is lower than that in the previously reported idealistic static images that were used.

This study also investigated the efficacy of concomitant use of confidence levels in the differential diagnosis of SSLs as a secondary analysis. As shown in Table 3, the sensitivity in the HC group was 82.4% and the upper limit of the 95% CI for sensitivity was 87.7%, indicating that sensitivity was unlikely to exceed 90%, even in the HC group. The multivariate logistic regression analysis of the usefulness of the eight endoscopic findings showed that mucus cap and dilated vessel were statistically significant findings. If mucus cap and dilated vessel are recognized with high confidence, the likelihood of SSLs may be high. Furthermore, if SSL had been diagnosed when any of the eight characteristic endoscopic findings were positive, the sensitivity would have been 123/129 (95%), which is sufficiently high. However, with a specificity of 20.5% and a negative predictive value of 75.0%, one in four lesions diagnosed during colonoscopy as HPs will be histopathologically diagnosed as SSL. It may be difficult to use this criterion as a differential diagnosis in clinical practice.

Unfortunately, these are based on the results of secondary analysis. Additional validation studies would be necessary.

The use of artificial intelligence (AI) to assist in the endoscopic diagnosis of SSLs is also being investigated [28-30]. A recent analysis of the diagnostic performance of AI reported sensitivity and specificity for SSLs of 80.9% and 62.1%, respectively [31]. Although these levels are similar to the results of this study and appear to be lower than expected, similar systems to date have sometimes excluded SSLs or failed to distinguish between SSLs and HPs [32, 33]. Currently, even with AI, accurate differential diagnosis between SSLs and HPs is expected to be difficult.

The present study had some limitations. First, when performing selective resection of SSLs, it is necessary to consider the diagnostic potential of including lesions other than serrated lesions, such as adenomas; however, lesions other than serrated lesions were excluded in this study. When excluded lesions are included, the diagnostic performance for SSLs in JNET type 1 lesions  $\geq 6$  mm was as follows: sensitivity, 79.8% (95% CI 74.7–84.4); specificity, 53.2% (46.8–59.0); accuracy, 67.6% (61.7–72.9); positive predictive value, 66.9% (62.3–71.0); and negative predictive value, 69.0% (60.7–76.5). The addition of the 21 excluded lesions does not affect the sensitivity of SSLs. In addition, this study excluded patients with serrated polyposis. Second, since the diagnosis of SSLs was defined based on an overall evaluation that included WLI, NBI, and magnified NBI, it was not possible to assess the extent to which these modalities affected the diagnosis. Lastly, the criteria for endoscopic findings were all subjective and vague. For example, it is not specified what degree of irregularity should be considered as "irregular" or "indistinct border". Thus, at present, there are no clear criteria for each finding. This point has been pointed out in earlier studies as a possible cause of inconsistency in judgments by the same observer or other observers [19]. Since this study was intended for the actual clinical setting, no ex-post analysis of these discrepancies was conducted.

In conclusion, the results of this study showed that the sensitivity of the differential diagnosis of SSLs was very unlikely to exceed 90% of the threshold value. Therefore, accurate differential diagnosis of SSLs and HPs using magnifying colonoscopy was challenging even for experts. JNET type 1 lesions  $\geq 6$  mm are recommended to be resected because selective endoscopic resection has a disadvantage of leaving approximately 20% of SSLs on site. Future advances are expected in the endoscopic differential diagnosis between SSLs and HPs.

## **Acknowledgement**

We would like to thank Honyaku Center Inc. for English language editing, Drs. Fumihiro Inoue, Hajime Honjo, Tomoyuki Nagai, Tomohiro Soda, Saori Kashiwagi, and Yoshio Sakamoto for their dedicated cooperation and high-quality colonoscopies.

## **Statement of Ethics**

This study was conducted in accordance with the Declaration of Helsinki and the Clinical Research Act. This study protocol was reviewed and approved by the Research Ethics Review Committee on December 5th, 2019, approval number 201912-02; it was also pre-registered in UMIN-CTR (University Hospital Medical Information Network Clinical Research Registration System) as UMIN ID: 000037543. Written informed consent was obtained from all participants.

## **Conflict of Interest Statement**

The authors have no conflicts of interest to declare.

## **Funding Sources**

This research received no specific grant from any funding agency in the public, commercial, or not-for-profit sectors.

## **Author Contributions**

Daizen Hirata, Akira Teramoto, Mineo Iwatate, Wataru Sano, Hiroshi Kashida, Yasushi Sano, and Yoshitaka Murakami designed the study; Daizen Hirata, Akira Teramoto, Mineo Iwatate, Santa Hattori, Mikio Fujita, Tsuguhiro Matsumoto, Chikara Ebisutani, Wataru Sano, Yoriaki Komeda, Hiroshi Kashida, Yasushi Sano, and Masatoshi Kudo recruited participants and data collection; Daizen Hirata, Mineo Iwatate, and Wataru Sano interpreted the data and performed statistical analysis; Daizen Hirata drafted the manuscript; Mineo Iwatate, Wataru Sano, Hiroshi Kashida, Yasushi Sano, Yoshitaka Murakami, and Masatoshi Kudo critically revised the manuscript for intellectual content; All authors approved the final version of the manuscript.

## **Data Availability Statement**

All data generated or analyzed during this study are included in this article. Further enquiries can be directed to the corresponding author.



## References

- 1 Sung H, Ferlay J, Siegel RL, Laversanne M, Soerjomataram I, Jemal A, et al. Global cancer statistics 2020: GLOBOCAN estimates of incidence and mortality worldwide for 36 cancers in 185 countries. *CA Cancer J Clin*. 2021 May;71(3):209–49.
- 2 Leggett B, Whitehall V. Role of the serrated pathway in colorectal cancer pathogenesis. *Gastroenterology*. 2010 Jun;138(6):2088–100.
- 3 IJspeert JE, Vermeulen L, Meijer GA, Dekker ESerrated neoplasia-role in colorectal carcinogenesis and clinical implications. *Nat Rev Gastroenterol Hepatol*. 2015 Jul;12(7):401–9.
- 4 Ferlitsch M, Moss A, Hassan C, Bhandari P, Dumonceau JM, Paspatis G, et al. Colorectal polypectomy and endoscopic mucosal resection (EMR): European Society of Gastrointestinal Endoscopy (ESGE) Clinical Guideline. *Endoscopy*. 2017 Mar;49(3):270–97.
- 5 Sano W, Sano Y, Iwatate M, Hasuike N, Hattori S, Kosaka H, et al. Prospective evaluation of the proportion of sessile serrated adenoma/polyps in endoscopically diagnosed colorectal polyps with hyperplastic features. *Endosc Int Open*. 2015 Aug;3(4):E354–8.
- 6 Sano W, Fujimori T, Ichikawa K, Sunakawa H, Utsumi T, Iwatate M, et al. Clinical and endoscopic evaluations of sessile serrated adenoma/polyps with cytological dysplasia. *J Gastroenterol Hepatol*. 2018 Aug;33(8):1454–60.
- 7 Hasegawa S, Mitsuyama K, Kawano H, Arita K, Maeyama Y, Akagi Y, et al. Endoscopic discrimination of sessile serrated adenomas from other serrated lesions. *Oncol Lett*. 2011 Sep 1;2(5):785–9.
- 8 Kashida H, Ikehara N, Hamatani S, Kudo SE, Kudo M. Endoscopic characteristics of colorectal serrated lesions. *Hepato-Gastroenterology*. 2011 Jul–Aug;58(109):1163–7.
- 9 Yamada M, Sakamoto T, Otake Y, Nakajima T, Kuchiba A, Taniguchi H, et al. Investigating endoscopic features of sessile serrated adenomas/polyps by using narrow-band imaging with optical magnification. *Gastrointest Endosc*. 2015 Jul;82(1):108–17.
- 10 Yamada A, Notohara K, Aoyama I, Miyoshi M, Miyamoto S, Fujii S, et al. Endoscopic features of sessile serrated adenoma and other serrated colorectal polyps. *Hepato-Gastroenterology*. 2011 Jan–Feb;58(105):45–51.
- 11 Ishigooka S, Nomoto M, Obinata N, Oishi Y, Sato Y, Nakatsu S, et al. Evaluation of magnifying colonoscopy in the diagnosis of serrated polyps. *World J Gastroenterol*. 2012 Aug 28;18(32):4308–16.

- 12 Tadepalli US, Feihel D, Miller KM, Itzkowitz SH, Freedman JS, Kornacki S, et al. A morphologic analysis of sessile serrated polyps observed during routine colonoscopy (with video). *Gastrointest Endosc.* 2011 Dec;74(6):1360–8.
- 13 Bouwens MW, van Herwaarden YJ, Winkens B, Rondagh EJ, de Ridder R, Riedl RG, et al. Endoscopic characterization of sessile serrated adenomas/polyps with and without dysplasia. *Endoscopy.* 2014 Mar;46(3):225–35.
- 14 Lee EJ, Kim MJ, Chun SM, Jang SJ, Kim DS, Lee DH, et al. Sessile serrated adenoma/polyps with a depressed surface: A rare form of sessile serrated adenoma/polyp. *Diagn Pathol.* 2015 Jun 20;10:75.
- 15 Kawasaki K, Kurahara K, Oshiro Y, Yanai S, Kobayashi H, Nakamura S, et al. Clinicopathologic features of inverted serrated lesions of the large bowel. *Digestion.* 2016;93(4):280–7.
- 16 Hazewinkel Y, López-Cerón M, East JE, Rastogi A, Pellisé M, Nakajima T, et al. Endoscopic features of sessile serrated adenomas: Validation by international experts using high-resolution white-light endoscopy and narrow-band imaging. *Gastrointest Endosc.* 2013 Jun;77(6):916–24.
- 17 IIspeert JE, Bastiaansen BA, van Leerdam ME, Meijer GA, van Eeden S, Sanduleanu S, et al. Development and validation of the WASP classification system for optical diagnosis of adenomas, hyperplastic polyps and sessile serrated adenomas/polyps. *Gut.* 2016 Jun;65(6):963–70.
- 18 Nakao Y, Saito S, Ohya T, Aihara H, Arihiro S, Kato T, et al. Endoscopic features of colorectal serrated lesions using image-enhanced endoscopy with pathological analysis. *Eur J Gastroenterol Hepatol.* 2013 Aug;25(8):981–8.
- 19 Uraoka T, Higashi R, Horii J, Harada K, Hori K, Okada H, et al. Prospective evaluation of endoscopic criteria characteristic of sessile serrated adenomas/polyps. *J Gastroenterol.* 2015 May;50(5):555–63.
- 20 Yamashina T, Takeuchi Y, Uedo N, Aoi K, Matsuura N, Nagai K, et al. Diagnostic features of sessile serrated adenoma/polyps on magnifying narrow band imaging: A prospective study of diagnostic accuracy. *J Gastroenterol Hepatol.* 2015 Jan;30(1):117–23.
- 21 Kimura T, Yamamoto E, Yamano HO, Suzuki H, Kamimae S, Nojima M, et al. A novel pit pattern identifies the precursor of colorectal cancer derived from sessile serrated adenoma. *Am J Gastroenterol.* 2012 Mar;107(3):460–9.
- 22 Sano W, Hirata D, Teramoto A, Iwatate M, Hattori S, Fujita M, et al. Serrated polyps of the colon and rectum: Remove or not? *World J Gastroenterol.* 2020 May 21;26(19):2276–85.

- 23 Sano Y, Tanaka S, Kudo SE, Saito S, Matsuda T, Wada Y, et al. Narrow-band imaging (NBI) magnifying endoscopic classification of colorectal tumors proposed by the Japan NBI Expert Team. *Dig Endosc.* 2016 Jul;28(5):526–33.
- 24 Iwatate M, Sano Y, Tanaka S, Kudo SE, Saito S, Matsuda T, et al. Validation study for development of the Japan NBI Expert Team classification of colorectal lesions. *Dig Endosc.* 2018 Sep;30(5):642–51.
- 25 Hirata D, Kashida H, Iwatate M, Tochio T, Teramoto A, Sano Y, et al. Effective use of the Japan Narrow Band Imaging Expert Team classification based on diagnostic performance and confidence level. *World J Clin Cases.* 2019 Sep 26;7(18):2658–65.
- 26 Kashida H. Endoscopic diagnosis of sessile serrated polyp: A systematic review. *Dig Endosc.* 2019 Jan;31(1):16–23.
- 27 Pai RK, Mäkinen MJ, Rosty C. Colorectal serrated lesions and polyps. in: Nagtegaal ID, Arends MJ, Odze RD, Lam AK, editors *WHO classification of tumours of the digestive system*. Lyon, France: IARC Press; 2019, p. 163–9.
- 28 Mori Y, Kudo SE, Ogawa Y, Misawa M, Takeda K, Kudo T, et al. Mo1991 can artificial intelligence correctly diagnose sessile serrated adenomas/polyps? *Gastrointest Endosc.* 2017;85(5). DOI: <https://doi.org/10.1016/j.gie.2017.03.1178>.
- 29 Zhu X, Nemoto D, Wang Y, Guo Z, Shen Y, Aizawa M, et al. Sa1923 detection and diagnosis of sessile serrated adenoma/polyps using convolutional neural network (artificial intelligence). *Gastrointest Endosc.* 2018;87(6). DOI: <https://doi.org/10.1016/j.gie.2018.04.445>.
- 30 Lafeuille P, Lambin T, Yzet C, Latif EH, Ordoqui N, Rivory J, et al. Flat colorectal sessile serrated polyp: An example of what artificial intelligence does not easily detect. *Endoscopy.* 2022 May;54(5):520–1.
- 31 Minegishi Y, Kudo SE, Miyata Y, Nemoto T, Mori K, Misawa M, et al. Comprehensive diagnostic performance of real-time characterization of colorectal lesions using an artificial intelligence-assisted system: A prospective study. *Gastroenterology.* 2022 Jul;163(1):323-325.e3.
- 32 Mori Y, Kudo SE, Misawa M, Saito Y, Ikematsu H, Hotta K, et al. Real-time use of artificial intelligence in identification of diminutive polyps during colonoscopy: A prospective study. *Ann Intern Med.* 2018 Sep 18;169(6):357–66.
- 33 Zachariah R, Samarasena J, Luba D, Duh E, Dao T, Requa J, et al. Prediction of polyp pathology using convolutional neural networks achieves “resect and discard” thresholds. *Am J Gastroenterol.* 2020 Jan;115(1):138–44.

## Figure Legends

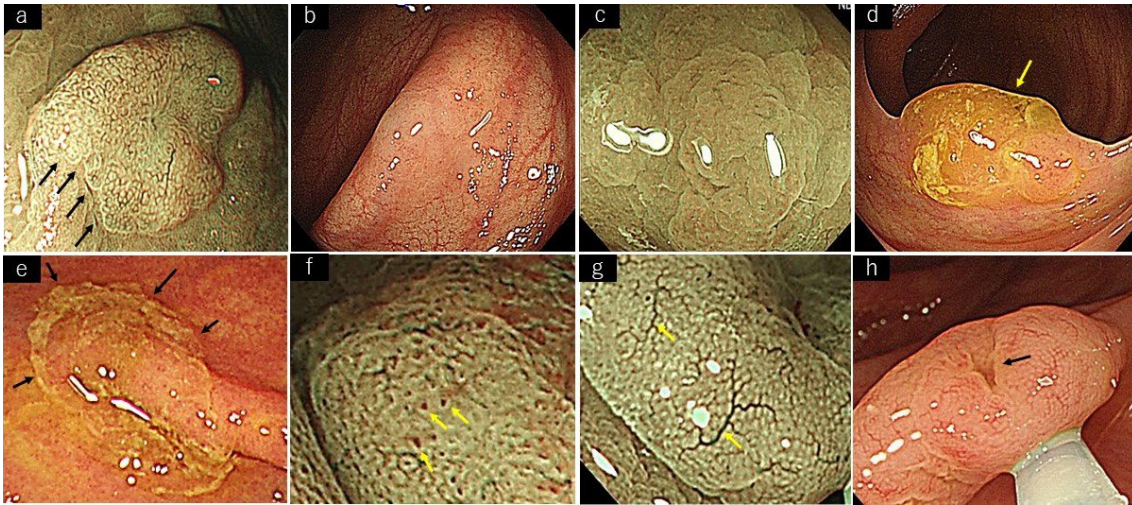


Fig. 1. Eight candidate findings of SSLs.

Fig. 1. a) Irregular shape, b) Indistinctive border, c) Cloud-like surface, d) Mucus cap, e) Rim of debris, f) Dilated vessels, g) Dilated crypts, h) Inverted growth pattern

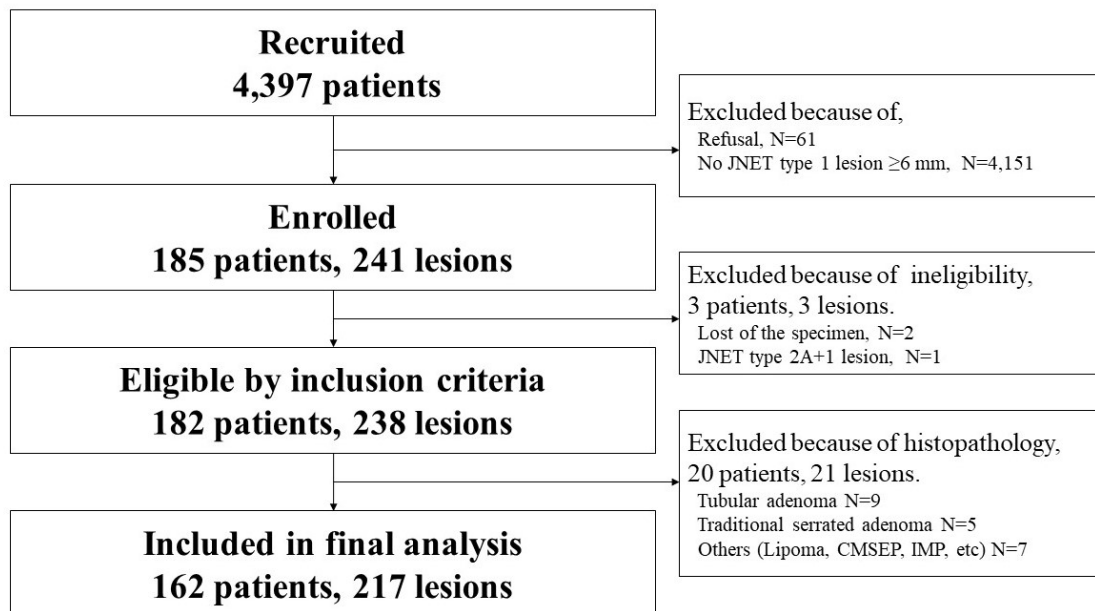


Fig. 2. Flowchart.

In four institutions, a total of 241 lesions from 185 cases were enrolled between December 2019 and October 2020 and no cases were denied enrolment. One lesion was excluded due to ineligibility, and 23 lesions were excluded due to non-serrated histology, eventually including 217 JNET type 1 lesions from 162 cases in the final analysis.

**Table 1. Baseline characteristics**

	<b>Overall</b>	<b>SSL</b>	<b>HP</b>	<b>P-value*</b>
<b>Patients</b>	162	103	72	
<b>Age (years)</b>	65.7 ± 10.3	65.4 ± 10.9	66.1 ± 9.6	0.571
<b>Sex ratio (male/female)</b>	89/73	44/59	49/23	<0.01
<b>Lesions</b>	217	129	88	
<b>Right colon (%)</b>	67.3	80.6	47.7	<0.01
<b>Mean size (mm)</b>	9.5 ± 5.0	10.8 ± 5.9	7.6 ± 2.8	<0.01
<b>Size: 6-9 mm</b>	148	73	75	<0.01
<b>Size: ≥ 10 mm</b>	69	56	13	<0.01

HP: hyperplastic polyp, SSL: sessile serrated lesion

\*: Comparison of SSL and HP

**Table 2. Differential diagnosis of SSLs and HPs in JNET type 1 lesions**

Endoscopic diagnosis	Pathological diagnosis	
	SSL	HP
SSL	103	36
	(61)	(14)
HP	26	52
	(13)	(26)

SSL: sessile serrated lesion, HP: hyperplastic polyp

( ): high confidence cases

**Table 3. Diagnostic performance of expert endoscopists in discriminating SSLs from HPs**

	Overall	High confidence
	N=217	N=114
Sensitivity	79.8% (74.7-84.4)	82.4% (76.1-87.7)
Specificity	59.1% (49.8-62.4)	65.0% (53.3-74.7)
Accuracy	71.4% (65.3-76.9)	76.3% (68.1-83.1)
PPV	74.1% (69.3-78.4)	81.3% (75.1-86.5)
NPV	66.7% (58.1-74.3)	66.7% (54.6-76.6)

PPV: Positive predict value, NPV: Negative predict value

( ): 95% confidence interval

**Table 4: Distribution of recognized endoscopic findings in SSLs and HPs**

No. of recognized endoscopic findings	SSL N=129	HP N=88
0	6	18
1	21	31
2	36	20
3	33	15
4	13	2
5	13	2
6	3	0
7	3	0
8	1	0
Average	2.76	1.52

SSL: sessile serrated lesion, HP: hyperplastic polyp



**Table 5: Appearance ratio of the eight findings in SSLs and HPs**

	SSL	HP	P-value
	N=129	N=88	
Irregular shape (%)	41.9	23.9	<0.01
Indistinctive border (%)	38.0	20.5	<0.01
Cloud-like surface (%)	20.9	8.0	<0.01
Mucus cap (%)	62.0	33.0	<0.01
Rim of debris (%)	16.3	9.1	0.13
Dilated vessel (%)	51.9	34.1	<0.01
Dilated crypt (%)	44.2	20.5	<0.01
Inverted growth pattern (%)	0.78	3.4	0.16

SSL: sessile serrated lesion, HP: hyperplastic polyp

**Table 6. Multivariate logistic regression analysis of eight endoscopic findings for SSLs**

Endoscopic findings	OR	95% CI	P-value
Irregular shape	1.884	0.959 - 3.698	0.066
Indistinctive border	1.811	0.895 - 3.667	0.099
Cloud-like surface	2.543	0.964 - 6.707	0.059
Mucus cap	2.262	1.212 - 4.223	<0.05
Rim of debris	1.760	0.652 - 4.750	0.265
Dilated vessel	1.997	1.062 - 3.756	<0.05
Dilated crypt	1.819	0.906 - 3.652	0.092
Inverted growth pattern	0.085	0.003 - 2.534	0.155

OR: odds ratio, CI: confidence interval